

Incidental Cannulation of Left Ventricular Thebesian Vein

Kalyan Chakravarthy Potu, MD
Jay N. Patel, MD
Majd Ibrahim, MD
Sujitha Sree Ketineni, MBBS
Sudhir Mungee, MD

A 52-year-old woman presented with chest pain from spontaneous coronary artery dissection of the distal segment of the first diagonal branch of the left anterior descending coronary artery. We performed left ventriculography, injecting 20 mL of contrast medium at 10 mL/s through a 5F, 100-cm Performa[®] Ultimate 1 diagnostic cardiac catheter with bumper tip and wire-braid design (Merit Medical Systems, Inc.). The opacified left ventricle (LV) showed mild anterolateral hypokinesis (estimated LV ejection fraction, 0.50). The catheter moved during the procedure, inadvertently cannulating a Thebesian vein with contrast injection (Fig. 1). The dye cleared in 30 seconds. The patient was discharged from the hospital the next day, in stable condition.

Comment

Described first by Vieussens¹ in 1706 and in detail by Thebesius² in 1708, Thebesian veins are rare intracardiac venous channels without valves. They enable direct communication between the heart chambers and the venous system or coronary arteries. They are thought to be more prevalent in the atria than in the ventricles and more prevalent in the right ventricle than in the LV.³

We incidentally encountered a rare LV Thebesian vein while performing left ventriculography. Our report includes a clinical angiographic video that shows LV Thebesian venous channels.

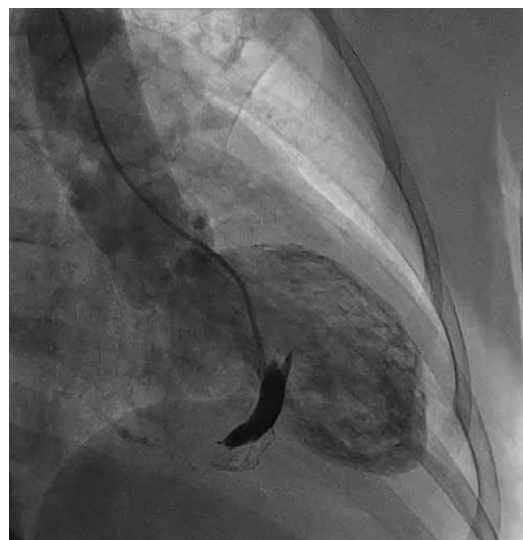


Fig. 1 Left ventriculogram shows inadvertent cannulation of a Thebesian vein, with contrast injection. The dye cleared in 30 seconds.

Supplemental motion image is available for [Figure 1](#).

Section Editor:

Raymond F. Stainback, MD

From: Department of Cardiology, University of Illinois College of Medicine at Peoria, Peoria, Illinois 61637

Address for reprints:

Kalyan Chakravarthy Potu, MD, 1301 W. Jefferson St., Suite 27-C, Morton, IL 61550

E-mail:

kpotu58@siumed.edu

© 2020 by the Texas Heart[®] Institute, Houston

References

1. Vieussens R. Nouvelles decouvertes sur le Coeur (New discoveries on the heart) [in French]. Toulouse (France): Jean Guillmette; 1706.
2. Thebesius AC. Disputatio medica inauguralis de circulo sanguinis in corde. Lugduni Batavorum; 1708.
3. Aqel R, Gupta R, Zoghbi GJ. Images in cardiology: Thebesian venous lake. Heart 2005;91(10):1318.