

Penetrating Atherosclerotic Ulcer of the Ascending Aorta

Found Incidentally in a 71-Year-Old Man

Antonino M. Grande, MD
Dario Di Perna, MD
Adele Valentini, MD
Eloisa Arbustini, MD

An asymptomatic 71-year-old man who had undergone a previous operation for carcinoma underwent computed tomographic (CT) angiography to determine cancer staging. The angiograms revealed severe atherosclerotic disease involving his aorta, coronary arteries, and both carotid arteries. The angiograms also showed intimal ulceration in the ascending aorta (Fig. 1). The lesion, a penetrating atherosclerotic ulcer (PAU), affected the anterior aspect of the patient's ascending

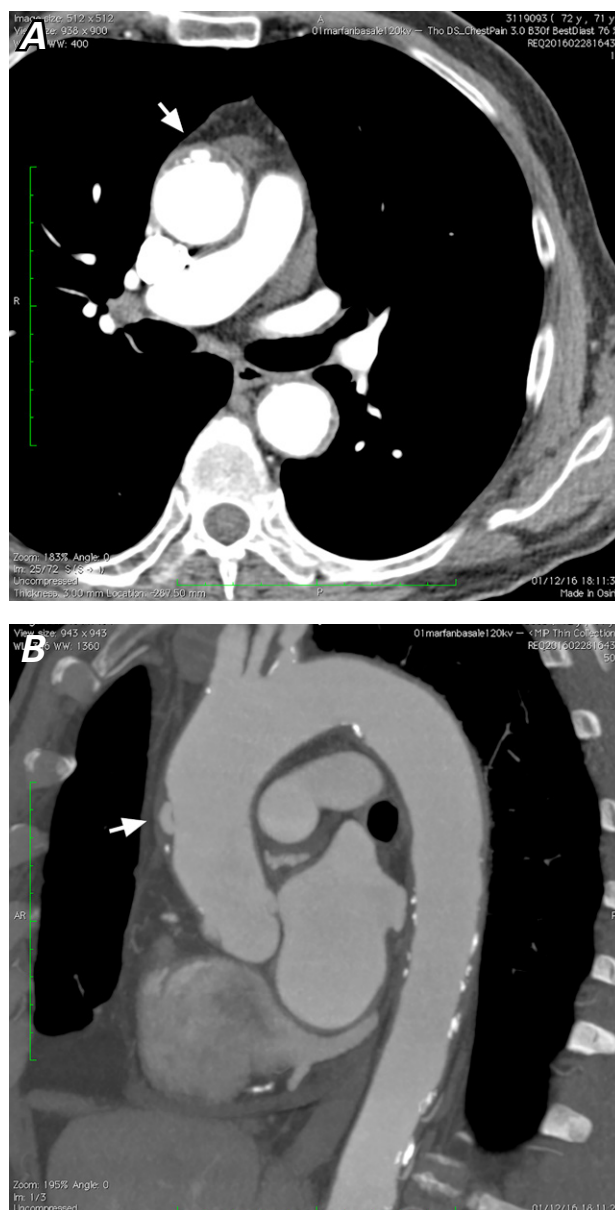


Fig. 1 Computed tomographic angiograms in the **A)** axial and **B)** lateral views show intimal ulceration of the ascending aorta caused by a penetrating ulcer. Arrows indicate the outpouching.

Section Editor:
Raymond F. Stainback, MD

From: Departments of Cardiac Surgery (Drs. Di Perna and Grande) and Radiology (Dr. Valentini), and Center for Inherited Cardiovascular Diseases (Dr. Arbustini), Fondazione IRCCS Policlinico San Matteo, 27100 Pavia, Italy

Address for reprints:
Antonino M. Grande, MD,
Fondazione IRCCS Policlinico
San Matteo, V.le C. Golgi,
19, 27100 Pavia, Italy

E-mail: amgrande@libero.it

© 2019 by the Texas Heart®
Institute, Houston

aorta, and the risk of progression to frank aortic dissection was great. Within a week of diagnosis, the patient underwent successful aortic replacement with a Dacron tube graft. Gross inspection and histologic evaluation of the aortic specimens revealed a large atherosclerotic plaque complicated by deep ulceration and intraplaque hemorrhage (Fig. 2).

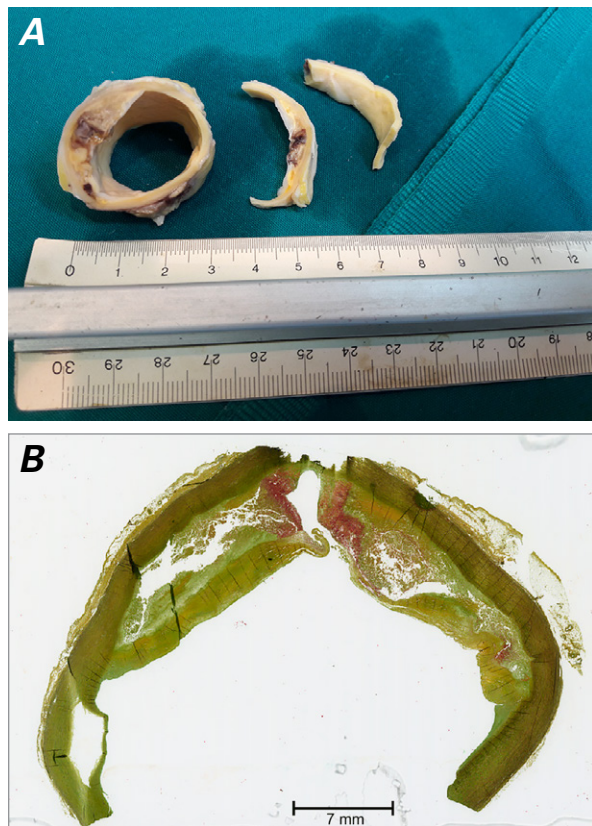


Fig. 2 **A)** Photograph shows gross specimens of the aorta; a large atherosclerotic plaque is complicated by a deep ulceration and intraplaque hemorrhage. **B)** Photomicrograph confirms severe atherosclerotic plaque complicated by a deep ulceration (Movat pentachrome stain, orig. $\times 100$).

Comment

Penetrating atherosclerotic ulcer and intramural hematoma are pathologic variants of classic aortic dissection; both are distinct in their presentation, natural history, and prognosis. The pathogenic mechanism of PAU stems from deep atherosclerotic lesions that compromise the innermost aortic layer, the intima. As the ulcer burrows into the aortic wall and penetrates the internal elastic lamina, blood enters the media (the middle aortic layer), resulting in surrounding hematoma.¹ In time, the ulcer may penetrate the outer aortic wall, resulting in rupture or dissection. Thus, the process of aortic layer separation in PAU differs from that of classic aortic dissection; notably, there is no intimal flap from an originating entry tear.¹ Although the pathology of PAU is distinctly different from that of classic aortic dissection, the lesion may progress and masquerade as aortic rupture, acute aortic dissection, pseudoaneurysm, or intramural hematoma.²

Our patient had no symptoms of aortic dissection, and his PAU was discovered incidentally. Although our belief is somewhat controversial, we think that prompt surgery to replace the affected segment of the aorta is indicated in cases of type A (Stanford classification) PAU, regardless of a lack of symptoms or relatively small lesion size.³

References

1. LeMaire SA, Gopaldas RR, Coselli JS. Thoracic aneurysms and aortic dissection. In: Brunicaardi FC, editor. *Schwartz's principles of surgery*. 10th ed. New York: McGraw-Hill Medical; 2014. p. 785-826.
2. Nathan DP, Boonn W, Lai E, Wang GJ, Desai N, Woo EY, et al. Presentation, complications, and natural history of penetrating atherosclerotic ulcer disease. *J Vasc Surg* 2012;55(1): 10-5.
3. Coady MA, Rizzo JA, Hammond GL, Pierce JG, Kopf GS, Elefteriades JA. Penetrating ulcer of the thoracic aorta: what is it? How do we recognize it? How do we manage it? *J Vasc Surg* 1998;27(6):1006-16.